

## Dabigatran and oesophagitis

### Introduction

Dabigatran (Pradaxa®) is a direct trombin inhibitor that is registered for i) *Primary prevention of venous thromboembolic events in adult patients who have undergone an elective total hip replacement surgery or total knee replacement surgery* ii) *Prevention of stroke and systemic embolism in adult patients with non-valvular atrial fibrillation (NVAf), with one or more risk factors* iii) *Treatment of deep vein thrombosis (DVT) and pulmonary embolism (PE), and prevention of recurrent DVT and PE in adults* (1). Dabigatran was granted marketing authorization in March 2008 (1).

Gastro-oesophagitis is a known adverse drug reaction of dabigatran which occurs rarely (> 1/10.000, <1/1000) when using dabigatran for primary VTE prevention after hip or knee replacement surgery and which is uncommon (> 1/1000, <1/100) when using dabigatran for the other indications (1).

The SmPC gives the following information about the administration of dabigatran: *“The capsules can be taken with or without food. Pradaxa® should be swallowed as a whole with a glass of water, to facilitate delivery to the stomach. Patients should be instructed not to open the capsule as this may increase the risk of bleeding”* (1).

In 2015 Lareb informed the Committee on Clinical Practice (Commissie Praktijk) of the Medicines Evaluation Board about the occurrence of oesophagitis when using dabigatran based on 7 reports, with the recommendation to change the information about the administration of the drug (2). The number of reports has since increased and this signal describes 33 reports of oesophagitis in relation to the use of dabigatran.

### Reports

Between 22-03-2013 and 29-10-2019 Lareb received 33 reports of oesophageal complaints in relation to the use of dabigatran, including one duplicate report. The reports concerned MedDRA Preferred Term (PT) Oesophagitis 8 reports, PT Oesophageal pain 21 reports, Burn oesophageal 4 reports and Oesophageal ulcer 1 report. One report can contain multiple adverse drug reactions (ADRs).

Table 1: Reports of oesophageal complaints in relation to dabigatran

Patient, Number, Sex, Age (yr), Source	Drug, daily dose Indication for use	Concomitant Medication	Suspected adverse drug reaction	Time to onset Action with drug Outcome
A, 180066 female, 70 years and older, medical doctor	dabigatran 110mg atrial fibrillation	digoxine, cholecalciferol, psyllium seeds, furosemide, bisacodyl, lidocaine vaseline, hypromellose/dextran 70, valsartan, levocetirizine, piroxicam, bisoprolol, risedroninic acid, fusidic acid, rabeprazole, paracetamol/codeine	Oesophagitis	4 weeks withdrawn recovering
B 153818 male, 60-70 years, cardiologist	dabigatran 150mg atrial fibrillation	furosemide, phenprocoumon, eplerenon, metoprolol, levothyroxine, quinapril	Oesophagitis	1 month withdrawn recovering
C 178906 female, 70 years and older, pharmacist	dabigatran 110mg not reported	atorvastatin, selenium sulphide, acenocoumarole, verapamil, digoxine, fosinopril, mometasone, pantoprazole	Oesophageal burn	4 days no change unknown
D, 179493 male, 60-70 years, patient	dabigatran 150mg atrial fibrillation	omeprazole, fluticasone	Oesophageal pain, headache, restlessness, stomach ache	36 hours withdrawn recovered

E, 166623 female, 70 years and older, pharmacist	dabigatran 110mg atrial fibrillation	valsartan, digoxine, furosemide, metoprolol	Oesophageal pain, swallowing difficulty, salivary hyper- secretion	2 days Drug withdrawn, unknown
F, 153407 male, 60-70 years, patient	dabigatran 75mg cardiac arrhythmia		Oesophageal pain, dysphagia, pyrosis	1 month Drug withdrawn recovered
G, 151610 female, 70 years and older, general practitioner	dabigatran 110mg atrial fibrillation	metoprolol, triamterene/ hydrochlorothiazide, clomipramine	Oesophageal ulcer, reflux oesophagitis, melaena	4 days Drug withdrawn, recovering
H NL-LRB- 204064, female, 70 years and older, Patient	dabigatran 150mg, cardiac arrhythmia		Oesophageal pain, sore throat	Days after start, hours after administration, unknown, recovering
I NL-LRB- 183428, female, 70 years and older, pharmacist	dabigatran 110mg, atrial fibrillation, verapamil 120mg, atrial fibrillation	macrogol, sulfasalazine, adalimumab, diclofenac, timolol,	Oesophageal pain, drug interaction	1 day after starting dabigatran, dabigatran withdrawn, verapamil dose not changed, recovered, positive rechallenge
J NL-LRB- 188971, female, 70 years and older, pharmacist	dabigatran 110mg, TIA	rosuvastatine, hydrochlorothiazide, amitriptyline, enalapril, codeine	Oesophageal pain, reflux oesophagitis, rash	6 days, dose not changed, recovered from rash, recovering from the other events
K NL-LRB- 202703, male 60-70 years, patient	dabigatran 150mg, arrhythmia	bisoprolol, flecainide	Oesophageal pain	1.5 years, dose not changed, recovered
L NL-LRB- 220747, 70 years and older male, pharmacist	dabigatran 110mg, atrial fibrillation	nifedipine, salbutamol, salmeterol/fluticason, simvastatin, tiotropium	Oesophageal pain, dyspnoea, dysphagia	2 days, withdrawn, unknown
M NL-LRB- 234112, female, 50-60 years ,patient	dabigatran 75mg, atrial fibrillation		Oesophageal pain	1 day, withdrawn, recovered
N NL-LRB- 239989, Male 60-70 years, patient	dabigatran 150mg, atrial fibrillation	omeprazole, sotalol, dorzolamide	Oesophageal pain, stomach ache	10 month, withdrawn, recovered
O NL-LRB- 241584, Female, 70 years and older other, health care professional	dabigatran 75mg, atrial fibrillation	amitriptyline, irbesartan, amlodipine, sotalol, pantoprazole, flecainide, cholecalciferol, ascorbinic acid	Dyspepsia, oesophageal pain	2 weeks, drug withdrawn, recovered
P NL-LRB- 245781, male, 60-70 years, patient	dabigatran 75mg, prophylaxis	digoxine, fosinopril, glicazide, metformine	Oesophageal pain, stomach ache	40 minutes, withdrawn, recovered
Q NL-LRB- 00251762, female, 70 years and older,	dabigatran 110mg, atrial fibrillation	metformine, amlodipine, hydrochlorothiazide, losartan, metoprolol, colecalfiferol,	Burning oesophagus	2 days, withdrawn, recovered

pharmacist		omeprazole, oxazepam, norriptyline, temazepam		
R NL-LRB-00276468, female, 50-60 years, patient	dabigatran 150mg, venous thrombosis, pulmonary thrombosis	nifedipine	Oesophageal pain, stomach ache	2 days, no change, recovering
S NL-LRB-00297510, female, 60-70 years, patient	dabigatran 150 mg, not reported		Burning oesophagus, haemorrhoids, stomach discomfort	1 month, withdrawn, recovered
T NL-LRB-00297633, male, 70 years and older, Patient	dabigatran 150mg, anti-coagulant	pantoprazole, fosinopril, nebivolol, amlodipine, spironolacton, atorvastatin	Oesophageal pain, chest pressure	3 weeks, unknown, recovering
U NL-LRB-00304592, female, 70 years and older, patient	dabigatran 110mg, cardiac arrythmia	verapamil, digoxine, furosemide, isosorbidenitrate, loperamide	Capsules get stuck in the oesophagus, oesophageal pain	1 minute after administration, no change, not recovered
V NL-LRB-312367, female, 70 years and older, Patient	dabigatran 150mg, not reported	flecainide, sotalol	Oesophageal pain, stomach pain	2 years, no change, not recovered
W NL-LRB-322001, Male, 70 years and older, Medical doctor	dabigatran 150mg, atrial fibrillation		Burning oesophagus	Unknow, withdrawn, recovered
X NL-LRB-00342795, female 60-70 years, patient	dabigatran150mg, atrial fibrillation	perindopril,	Oesophageal pain	15 minutes, not changed, recovering
Y NL-LRB-00348391, male, 60-70 years ,pharmacist	dabigatran 75mg, atrial fibrillation	alirocumab, bisoprolol, ezetimib, isosorbinenitrate, coal tar/levomenthol	Medication stuck in throat, burn oesophageal, oesophageal pain	2 hours after administration, withdrawn, recovered
Z NL-LRB-186494, female, 60-70 years general practitioner = Dupicate with NL-Boehringer Ingelheim GmbH, Germany-2014-59808NL	dabigatran 150mg, atrial fibrillation	flecainide, metoprolol	Oesophagitis (after capsule got stuck in the oesophagus)	18 days, withdrawn, recovered
AA NL-LRB-227083, male, 70 years and older, patient	dabigatran 150mg, cardioversie	sotalol	Oesophagitis, gastritis	1 day, withdrawn, recovering
AB NL-LRB-243306, female, 30-40 years, Medical doctor	dabigatran 150mg, atrial fibrillation	metoprolol/irbesartan/hyd rochlorothiazide	Oesophagitis, gastroesophageal reflux	7 days, withdrawn, unknown
AC NL-LRB-00276994,	dabigatran 110mg, anti-coagulant	allopurinol, colecalciferol, digoxine, metoprolol,	Oesophageal ulcer, oesophagitis	2 years, withdrawn, recovered

male, 70 years and older, pharmacist		isosorbidenitrate, pantoprazole, simvastatin		
AD NL-LRB-229002, female, 60-70 years, pharmacist	dabigatran 110mg, atrial fibrillation clopidogrel 75mg, Chronic ischaemic heart disease, unspecified	pantoprazole, nitroglycerine, isosorbidenitrate, sotalol, amlodipine, losartan, simvastatin, alprazolam, vitamine B complex,	Oesophageal burn, drug interaction	1 month, dose not changed, not recovered
AE NL-BoehringerIngelheim-2019-BI-032729, female, 70 years and older, Literature report via MAH	dabigatran 110 mg, atrial fibrillation	bisoprolol, furosemide, digoxine, valsartan, risedronic acid, rabeprazole	Oesophagitis, epistaxis	6 weeks, withdrawn, recovered
AF NL-BoehringerIngelheim-2019-BI-006112, F, 70, via MAH	dabigatran 110 mg		Oesophagal burn	Unknown, Dose not changed, recovering

Some of the reports describe problems around the administration of the dabigatran capsules.

A: Reporter states: *Oesophageal complaints are relative unknown and the Farmacotherapeutische Kompas does not mention that the drug should be administered as the bisphosphonates, with plenty of water and at least 30 minutes in a right standing/sitting position.*

C: Reporter states: *"Patient suffers from a burning sensation in the oesophagus after administration of dabigatran which disappears after about an hour. Patient always takes the capsules with plenty of water"*

D: The patient states that he does not use a full glass of water when taking the capsules. The patient takes the capsules in the morning when having breakfast and in the evening together with dinner. He does not lie down shortly after ingesting the capsules.

F: The patient administered the capsules with plenty of water in the morning and after brushing the teeth in the evening before he went to bed (lying down shortly after administration).

H: The patient says that the complaints do not occur if she stands or sits for 30 minutes after ingestion of the capsules.

K: Moment of ingestion is changed from after dinner to before dinner.

N: The pain is the worst 30 minutes after ingestion of the capsules.

T: The pain is heavier when lying down, sitting or standing is less painful. After cardioconversion (planned) are the complaints recovering.

U: Despite ingesting dabigatran with plenty of water in a standing position, the complaints occurred.

V: Patient says that the complaints occur when she goes to bed within an hour after taking the drug.

X: Capsules are ingested in the evening and the pain occurs when the patient goes to bed. Because of the pain she has to sit upright in bed. After 24 hours the patient still feels the pain. The patient was advised by her physician to continue with the treatment and added a PPI.

Y: Patient ingested the capsules with water 2 minutes before going to bed. After two hours the complaints started and these persisted for 5 days. After this episode that patient ingests the capsules earlier and does not experience any complaints. Dabigatran is later stopped but not because of this adverse drug reaction.

Z: Oesophagitis was treated with pantoprazole. Because of the oesophagitis the patient stopped with dabigatran on own initiative, one week later the patient had a CVA.

AE: A 70 years and older female patient, who was on dabigatran 110 milligrams, twice a day, for the treatment of Atrial fibrillation, experienced dabigatran- induced esophagitis and recurrent epistaxis. The patient came to the emergency room for nausea and black stools for 3 weeks. Her medical history reported, for which she used fenprocoumon until recently, at the time of the report. This had been converted to dabigatran 100 milligrams twice daily 6 weeks prior to her visit to the emergency room due to recurrent epistaxis with an increase international normalized ratio (INR). On physical examination it was found that the patient seems pale, moderately ill with a blood pressure of 90/43 mmHg. Rectal examination showed melena. Laboratory tests showed a hemoglobin value of 3.6 mmol/l (reference value: 7.2 - 9.5 mmol/l), while 6 weeks earlier it was 6.8 mmol/l. The patient received 3 units of erythrocyte concentrate. An esophago-gastroduodenoscopy showed elongated ulcers with exfoliation in the mid-distal part of the oesophagus. Histopathological examination of oesophageal biopsies showed ulcerative inflammation without evidence of malignancy. The dabigatran was permanently discontinued, while the risedronic acid was continued. In addition to a liquid diet, the patient was also given intravenous esomeprazole 40 milligrams twice daily. Upon inspection of the

stool, no melena was seen afterwards and the patient was able to leave the hospital 3 days later, after the symptoms had subsided. After a week the complaints were completely gone. A control-scopy after 8 weeks showed a fully recovered oesophageal mucosa. Both events were treated. The event dabigatran-induced esophagitis was related to drug dabigatran. The patient recovered from both events.

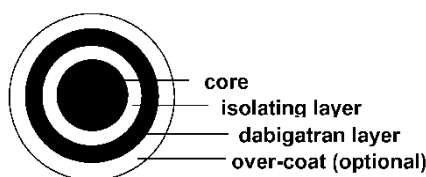
Based on: van der Voorn en Abha Bhalla M. Dabigatran-induced esophagitis. Gastrointestinal-liverdisease; Huisartsgeneeskunde. 2019 JUN 28;163:D3228:.

AF: The patient does swallow the dabigatran capsules with a big glass of water.

In a number of reports the oesophageal complaints are being treated with a Proton Pump Inhibitor. The oesophageal complaints also lead to switching to another NOAC or a cumarine. In report Z the patient had so much problems with the oesophageal complaints that he stopped the drug on his own initiative, one week later he got a CVA.

## Literature

Dabigatran capsules contain dabigatran etexilaat (pro-drug) pellets with a core of tartaric acid. This core consists of tartaric acid crystals (0.4-0.6mm) which are sprayed with a solution of acacia and tartaric acid in water (so called powder layering). The isolating layer consists of hydroxypropylmethyl cellulose (HPMC) which function is to separate the acid sensitive pharmaceutically active ingredient from the tartaric acid layer. (3).



*“Dabigatran etexilate is more consistently absorbed in an acidic environment in the gastrointestinal tract. Thus, to address potential problems with inconsistent absorption, a formulation was developed containing tartaric acid. A dabigatran etexilate coating is applied onto a tartaric acid core to form tiny pellets (≈1-mm diameter) that are placed in a capsule. A clinical capsule contains hundreds of these pellets, the exact number depending on the dose strength of the capsule. In this way dabigatran etexilate absorption is not dependent on the gastrointestinal acidity of the patient but brings its optimal pH environment with it, reducing variability even with proton pump inhibitor coadministration. (2). After oral administration, dabigatran etexilate is rapidly absorbed and quickly and completely hydrolyzed to its active moiety, dabigatran, by nonspecific ubiquitous esterases in the gut, plasma, and liver. Because bioconversion of dabigatran etexilate begins in the gut, the drug enters the portal vein as a combination of prodrug and active compound. The absolute bioavailability after oral administration of dabigatran etexilate is only ≈6.5%. (3) “*

Ykema *et al* describe a case of dabigatran induced oesophagitis in the NTVG in 2019 (4) as well as literature review about this subject. The literature review reveals that there are 26 patients described with dabigatran induced oesophagitis.

eerste auteur	aantal patiënten	symptomen	endoscopische bevindingen	beloop
Okada <sup>1</sup>	1	retrosternale pijn, odynofagie, dysfagie	- longitudinale exfoliatieve mid-oesofagitis - circumferentieel ulcus distale oesofagus met 'casts'*	gezezen
Dumkow <sup>2,2</sup>	1	melena	- niet beschreven	overleden
Zimmer <sup>10</sup>	1	retrosternale pijn, odynofagie	- exfoliatieve oesofagitis met casts distale oesofagus - irregulair nodulair segment mid-oesofagus	maligniteit
Ootani <sup>4</sup>	2	retrosternale pijn, odynofagie, dysfagie	- 'kissing' ulcera mid-oesofagus	gezezen
Ueta <sup>13</sup>	1	pijn na inname dabigatran	- longitudinale exfoliatieve mucosa mid-oesofagus	gezezen
Yoshimitsu <sup>11</sup>	1	pijn in bovenbuik	- longitudinale exfoliatieve mucosa mid-oesofagus	gezezen
Toya <sup>5</sup>	19	pijn, odynofagie, dysfagie, reflux, melena	- longitudinale exfoliatieve mucosa (94,7%), - circumferentiële erosies (10,5%) mid- tot distale oesofagus	gezezen

\* Een 'cast' is een afdruk van de etsende stof in de slokdarmwand

Figure 1: Literature cases describing dabigatran induced oesophagitis (4).

Medication induced oesophagitis occurs through pill retention in the oesophagus and direct contact with the mucosa (5). The injury usually occurs in the middle of the oesophagus because the lumen here is physiologically narrowed through external pressure of the aorta arch. Patients with polypharmacy, decreased fluid intake and cardiac dilatation have an increased risk of medication induced oesophagitis. Other risk factors are decreased salivary secretion, motility disturbances, strictures and malignancies of the oesophagus (6, 7).

The treatment of dabigatran induced oesophagitis consists of temporarily withdrawing the drug and administration of a PPI. After withdrawing dabigatran, the symptoms mostly disappear after 7-10 days. The prognosis is good, in the cases described in literature, 92% recover (4).

## Conclusion

The occurrence of oesophagitis when using dabigatran can possibly be related to the damaging effects of tartaric acid on the oesophageal mucosa. The literature states, that to prevent oesophagitis, the patient need to be instructed to take dabigatran with plenty of water and then stay in an upright position (standing or sitting) for 30 minutes (4-10). What the current SmPC of dabigatran says: *"Pradaxa should be swallowed as a whole with a glass of water, to facilitate delivery to the stomach"* seems to be insufficient for the prevention of oesophagitis and other oesophageal complaints. In some of the cases a proton-pump-inhibitor was also used by the patient. It is not clear if those patients already suffered from gastritis before dabigatran was prescribed or if the drug was used to treat complaints after dabigatran was initiated or was used a prophylaxis.

The reports received by Lareb show that in a number of cases the reporters explicitly mention problems around the ingestion of the capsules, especially when not keeping an upright position. It should be considered providing a more detailed instruction for the ingestion of dabigatran capsules to reduce the chance of oesophagitis.

## References

1. College ter Beoordeling van Geneesmiddelen. SmPC Pradaxa 2019 [updated 06-07-2019. Available from: [https://www.geneesmiddeleninformatiebank.nl/ords/f?p=111:3::SEARCH:NO::P0\\_DOMAIN,P0\\_LANG,P3\\_RVG1:H,NL,73883](https://www.geneesmiddeleninformatiebank.nl/ords/f?p=111:3::SEARCH:NO::P0_DOMAIN,P0_LANG,P3_RVG1:H,NL,73883).
2. Bijwerkingencentrum Lareb. Commissie Praktijk: Dabigatran en oesofagitis 2015 [updated 04-201528-10-2019]. Available from: [https://databankws.lareb.nl/Downloads/Commissie\\_Praktijk\\_dabigatran\\_Nov2014.pdf](https://databankws.lareb.nl/Downloads/Commissie_Praktijk_dabigatran_Nov2014.pdf).
3. Kroselj VNMS, inventorPharmaceutical oral dosage forms comprising dabigatran etexilate and its pharmaceutically acceptable salts United States2013.
4. Ykema BLM, van der Voorn M, Bhalla A. [Dabigatran-induced oesophagitis]. Ned Tijdschr Geneesk. 2019;163.
5. Kikendall JW, Friedman AC, Oyewole MA, Fleischer D, Johnson LF. Pill-induced esophageal injury. Case reports and review of the medical literature. Dig Dis Sci. 1983;28(2):174-82.
6. Toya Y, Nakamura S, Tomita K, Matsuda N, Abe K, Abiko Y, et al. Dabigatran-induced esophagitis: The prevalence and endoscopic characteristics. J Gastroenterol Hepatol. 2016;31(3):610-4.
7. Zografos GN, Georgiadou D, Thomas D, Kaltsas G, Digalakis M. Drug-induced esophagitis. Dis Esophagus. 2009;22(8):633-7.
8. Okada M, Okada K. Exfoliative esophagitis and esophageal ulcer induced by dabigatran. Endoscopy. 2012;44 Suppl 2 UCTN:E23-4.
9. Miller CS, Dorreen A, Martel M, Huynh T, Barkun AN. Risk of Gastrointestinal Bleeding in Patients Taking Non-Vitamin K Antagonist Oral Anticoagulants: A Systematic Review and Meta-analysis. Clin Gastroenterol Hepatol. 2017;15(11):1674-83 e3.

10. Connolly SJ, Ezekowitz MD, Yusuf S, Eikelboom J, Oldgren J, Parekh A, et al. Dabigatran versus warfarin in patients with atrial fibrillation. N Engl J Med. 2009;361(12):1139-51.

*This signal has been raised on January 9, 2020. It is possible that in the meantime other information became available. For the latest information, including the official SmPC's, please refer to website of the MEB [www.cbq-meb.nl](http://www.cbq-meb.nl)*